

## GIANT DUODENAL ULCER

Kamal Serrar, Yasser El Oukli, Mohammed Maliqi, Youssef Kerroum, Amraoui Mohammed.  
Medical School of Rabat, Med V<sup>th</sup> University Hospital Rabat, Morocco.  
Surgical emergency department, Ibn Sina University Hospital, Rabat, Morocco.

### ABSTRACT

Peptic Ulcerative disease is a common medical emergency. In Moroccan context, incidence of duodenal ulcers has been reported as prominent cause of acute upper gastrointestinal bleeding [1]. We're presenting here a spectacular presentation of duodenal ulcer.

A 60 year-old man, hypertensive with medical history of hemorrhagic stroke, was admitted to the hospital emergently complaining from severe abdominal pain and vomiting. Clinical examination showed an evidence of acute peritonitis. Laparotomy revealed a large perforated duodenal ulcer, measuring 6cm diameter, treated by surgical repair (surgical sutures) with good evolution.

**Keywords:** Diameter, Giant Duodenal Ulcer.

### Corresponding Author:

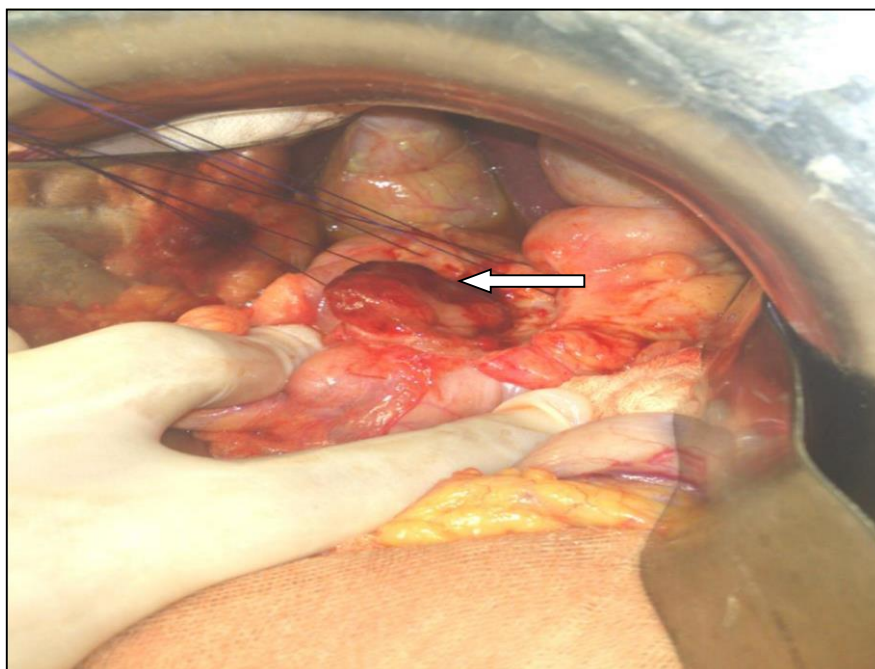
Dr. K. Serrar, MD.

**Address:** Surgical emergency department, Ibn Sina University Hospital, Rabat, Morocco.

**E-mail :** [kamalserrar@gmail.com](mailto:kamalserrar@gmail.com)

**Tel:** + (212) 651964102

**Copyright © 2012- 2018 Dr K. Serrar.** This is an open access article published under **Creative Commons Attribution -Non Commercial- No Derivs 4.0 International Public License (CC BY-NC-ND)**. This license allows others to download the articles and share them with others as long as they credit you, but they can't change them in any way or use them commercially.



[1] [Cherradi Y, Timraz A., Essamri W., Benelbarhdadi I., Ajana FZ, Afifi R., and al. Incidence and Clinical Features of Peptic Ulcer Disease in Acute Upper Gastrointestinal Bleeding: -Experience of Moroccan University Hospital Unit- Journal of Medical and Surgical Research – JMSR 2015 Vol. II \(2\): 140-143.](#)