

INTRAPERITONEAL VUE OF A PNEUMATOSIS INTESTINALIS

El Hamid Mohammadine
Chirurgie B department, Ibn Sina university hospital, Rabat, Morocco

Corresponding author:

Pr El Hamid Mohammadine
Chirurgie B department, Ibn Sina university hospital, Rabat, Morocco
E-mail : hamidmohammadine@gmail.com

*Copyright © 2012- 2014. Mohammadine EH. and al. This is an open access article published under **Creative Commons Attribution-NonCommercial-NoDerivs 4.0 International Public License (CC BY-NC-ND)**. This license allows others to download the articles and share them with others as long as they credit you, but they can't change them in any way or use them commercially.*

Intraperitoneal vue of a Pneumatosis Intestinalis ,a rare disease wich is characterised by the presence of gas within the wall of small or large intestine .thoses cysts could have pneumoperitoine without Intestinalis perforation . The pathogenesis is poorly understood .All of the cases ,We have seen et are associated to stenosis bulbare ulcer as in this picture (Figure 1) .The bulbar surgery (Pyloroplasty) lead to disappearance of pneumatosis .

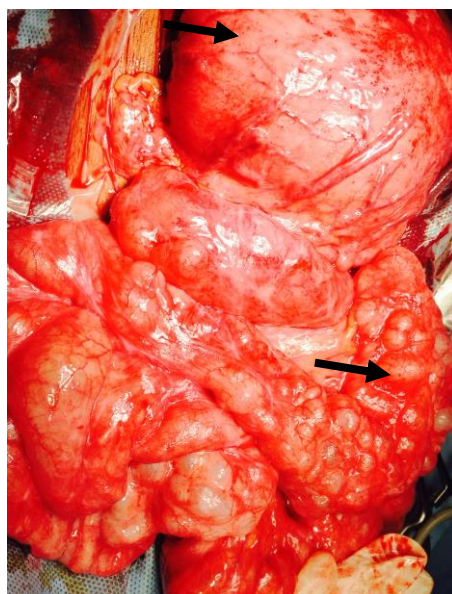


Figure 1 : Cysts in small intestine with large stomach caused by bulbar ulcer.

Key words: bulbar ulcer; Pneumatosis; intestinal cysts