

## FUNCTIONAL PARAGANGLIOMA OF THE ORGAN OF ZUCKERKANDL: A CASE REPORT

M.S. Naya<sup>1,3</sup>, M. Hamid<sup>1,3</sup>, L. Jaiteh<sup>1,3</sup>, M. Tbouda<sup>2,3</sup>, A. Jahid<sup>2,3</sup>, Y. Kerroum<sup>1,3</sup>, YZ. Khedid<sup>1,3</sup>, M. Echarrab<sup>1,2,3</sup>, M. El Ounani<sup>1,2,3</sup>, F. El Alami<sup>1,2,3</sup>, M. Amraoui<sup>1,2,3</sup>, A. Errougani<sup>1,2,3</sup>, M.R. Chkoff<sup>1,2,3</sup>, M El Absi<sup>1,2,3</sup>

<sup>1</sup>Surgical Emergencies Dep<sup>t</sup>, Ibn Sina University Hospital, Rabat, Morocco.

<sup>2</sup>Pathology Dep<sup>t</sup>, IbnSina University Hospital, Rabat, Morocco

<sup>3</sup>Medical School of Rabat, Mohammed V<sup>th</sup> University Hospital, Rabat, Morocco.

### Corresponding Author:

Dr. M.S. Naya, MD.

Address: Surgical Emergencies Dept, Ibn Sina University Hospital, Rabat, Morocco.

**Copyright © 2012- 2018.** Dr **M.S. Naya** and al. This is an open access article published under **Creative Commons Attribution -Non Commercial- No Derives 4.0 International Public License (CC BY-NC-ND)**. This license allows others to download the articles and share them with others as long as they credit you, but they can't change them in anyway or use them commercially.

### Case Presentation:

A 24-year-old patient at 3 months postpartum with a history of gestational hypertension, presented at the emergency department for a headache, irritability, palpitation and abdominal pain. Physical examinations showed skin pallor, tachycardia at 110 bpm as well as a hypertensive peak of 220/100 mmHg. However the patient admitted to taking calcium channel blockers and beta blockers since her pregnancy. There was no abdominal distension or palpable mass.

Laboratory tests showed anemia at 7 g/dl which required a transfusion and the rest of the lab results were within normal range. Blood and urinary levels of methoxylated derivatives were high: urinary Noradrenaline: 4510 µg/24 h (normal: < 500) and blood Noradrenaline: 51860 ng/l (normal: <3000), Normetanephrine: 1300 (Normal: <1200). However, Adrenaline, Dopamine and metanephrine were within normal range).

The abdominal angio-CT scan performed, showed a polylobate retroperitoneal mass situated on latero-aortic surface and under the left kidney in close contact with the psoas muscle. The mass measured 7.2 cm on its longest axis and 5 cm in thickness with a tissue-like nature inferiorly, hypodense superiorly and contrast enhancing externally. There was a mass effect on the branches of the superior mesenteric vein externally without any signs of invasion or lymphadenopathies. (FIG. 1)

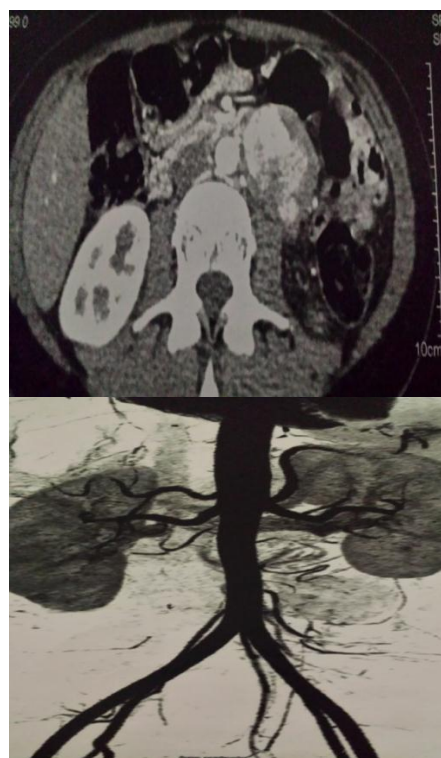

Fig 1: CT image of the paraganglioma of the organ of Zuckerkandl.

The patient was operated on and the approach was through a midline incision. Surgical exploration found a tumor below the left kidney and in front of and in close contact with the terminal aspect of the aorta which extended down to its bifurcation into the two primitive iliac vessels. The tumor was first resected posteriorly and away from the left ureter and then control of its vasculature was obtained in order to assure hemodynamic stability for the rest of the operation. Resection of the tumor was then completed in a monobloc fashion with a nearby adenopathy. The patient was transferred postoperatively to the intensive care unit. (Figure 2)

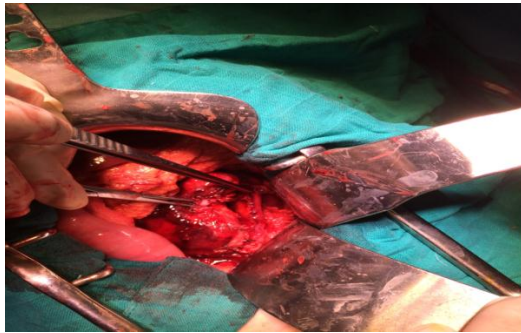

Figure 2: Vascular proximity of the paraganglioma

The histopathological examination of the tumor and of what was believed to be an accompanying adenopathy showed that the two samples had the same histological appearance and that no lymph node tissues were found. Detailed analysis showed tumor proliferation made of nested strands supported spans by spindle-shaped cells producing a Zellballen aspect within a richly vascularized stroma. Tumor cells had pleomorphic nuclei and a finely granular eosinophilic cytoplasm. Mitosis was rare and the proliferation contained focal hemorrhagic suffusions and fibrous remodeling. The mass was well limited by a thick fibrous capsule and there was no vascular embolus.

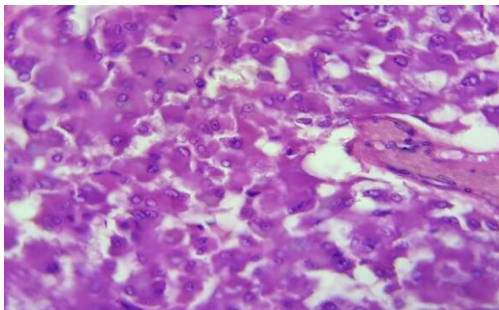


Figure 4: Low-power microscopy revealing a carcinomatous tumor of alveolar architecture (hematoxylin and eosin, original magnification,  $\times 10$ )

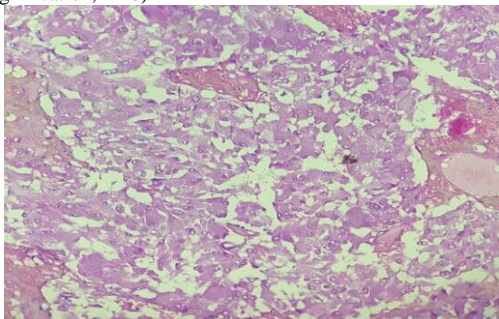


Figure 4: High-power microscopy showing bland appearing cuboidal cells with small round nuclei and granular cytoplasm (hematoxylin and eosin; original magnification,  $\times 40$ )

## DISCUSSION

Paraganglioma is defined as a benign or malignant tumor of the extra-adrenal paraganglion system that develops from ectodermal cells of the embryonic autonomic nervous system of the primitive chromaffin tissues which form the sympathetic ganglia of the para-vertebral chain[2] (1). It may or may not be functional (2). In contrast, pheochromocytomas are located in the adrenal gland itself (3). Our case is about a paraganglioma at the lower end of the abdominal aorta to the organ of Zuckerkandl, the embryonic vestige of the paraganglionic system between the origin of the inferior mesenteric artery and the aortic bifurcation. (2) It is an organ present in the fetus which may persist as a fibrous residue in the para-aortic nerve plexus. (2).

## Epidemiology

This is a tumor that affects all races but is less frequent in the black race. Its reported incidence is between 2 and 8 cases per million (1,2) (4) meaning 0.005% to 0.1% in the general population [1]. (5) The prevalence of these neuroendocrine tumors is estimated at 4% in the context of an adrenal incidentaloma and 0.1% in the context of hypertension [1]. (6) This is a tumor that may appear at any age preferentially between 3rd and 5th decades with a sex ratio close to 1 (7). (2) (4.5). (4) Paraganglioma of the Zuckerkandl organ is a rarity (3) (2) and it is more frequently functional than non-functional. Less than one hundred cases are reported in the literature (4-6). (2) Ninety per cent of them are of adrenal origin, making up the pheochromocytoma group. The remaining 10% comes from the autonomic nervous system. Management of pheochromocytoma / paraganglioma should be carried out by multidisciplinary teams in expert centers (7) (8) because of the risk of tumor malignancy, the severity of the complications and the curable nature of the condition. (6). The steps of this management are based on diagnosis of catecholaminergic hypersecretion, tumor location, search for possible metastases. It also includes therapeutic management by surgical excision and possible adjuvant treatment as well as genetic diagnosis and follow-up (6)

## Clinical diagnosis

Diagnosis of functional paragangliomas is generally earlier than that of non-functional tumors [4,5]. (8) It is suspected in our patient with hypertension resistant to medical treatment (principle symptom) associated with palpitations. Her antihypertensive treatment could have however been modified before

concluding a resistance to treatment and supplementary imaging studies could have been performed thus allowing for earlier diagnosis. (6) The review of the literature has shown that the clinical evidence of a paraganglioma is the typical symptomatology of catecholaminergic hypersecretion, juvenile or resistant hypertension, adrenal incidentaloma, genetic predisposition or typical clinical presentation. (6) The symptoms of functional pheochromocytomas and paragangliomas are summarized by the "6 Ps": 1. Pressure 2. Pain (head, chest, abdominal) 3. Perspiration 4. Palpitation 5. Pallor 6. Paroxysms.

(3) At least 1 of these 6 symptoms can be found in most patients, which means that the probability of disease is very low in totally asymptomatic patients (3).

### Laboratory Test

The measurement of levels of catecholamines and their metabolites may provide information on the location and sometimes also on the probable malignancy of the tumor. (3) As a rule, only levels of more than three times the upper limit of normal values are considered to be clearly pathological.

**Table I:** Catecholamine metabolism and diagnostic orientation (1)

Catecholamine	Metabolites	Interpretation
Dopamine	Methoxytyramine	Associated with malignancy
Noradrenaline	Normetanephrine	With pheochromocytoma associated with VHL. Functional paraganglioma
Adrenaline	Metanephrine	Pheochromatytoma Associated with at MEN2 mutation

Our case shows lab test results compatible with a functional paraganglioma given the high levels of Noradrenaline (20 times normal levels). Other tests would include measurement of the blood and urine levels of other catecholamines and especially of chromogranin A (2)

### Imaging Studies

Initial imaging studies are performed with an MRI or CT scan of the abdomen, as each has a sensitivity of about 95% (3) On a CT scan, the tumor appears as homogeneous or heterogeneous solid masses of variable sizes and on an MRI it appears hypointense or iso-intense on T1, hyperintense on T2. (9). However, these imaging modalities cannot determine the functional or nonfunctional nature of the tumor. Scintigraphy can help in detecting functional tumors, multiples tumors as well as possible metastases (3) (9)

Treatment: Surgery remains the only curative form of management if resection is complete. [8-10]. (8) (10) Certain authors suggest the introduction of calcium channel blockers as well as beta-blockers a week prior to surgery (5). Surgery in our patient was through an open laparotomy given the close proximity the tumor to the great vessels which would made laparoscopic surgery a difficult choice (8). Parameters such as operating time and amount of blood loss tend to influence the degree of success of the surgery (5). Adjuvant chemotherapy or radiation therapy is not necessary in the management of paraganglioma (4). According to Xu and al, there are four minor postoperative complications: wound infection, lymphorrhoea, deep vein thrombosis of the lower limbs, and pneumonia.

### Malignancy

Malignancy can be suspected in case of the presence of metastases at diagnosis or in the case of urinary hyper-secretion of hormonal precursors prior to surgery, or in the presence of secondary tumor sites (10) (8).

Genetic testing should be offered to all patients. Some mutations are correlated with a high risk of malignancy and poor prognosis, especially those involving the SDHB gene. (6) The search for mutations on susceptible genes to find out if the paraganglioma falls within a hereditary framework. This should lead to the extension of the genetic survey and the screening of first degree parents (6). In our patient, the paraganglioma probably does not fit within a hereditary framework.

### Conclusion

The rare paraganglioma of the zuckercandl organ must not eliminate it in front of any rebellious hypertension at medical treatment and its malignancy should not be ruled out despite the absence of loco-regional invasion or metastasis, because a recurrence at a distance is always possible especially if the surgical excision is not sufficiently radical.

**There is no conflict of interest.**

## REFERENCES

1. M. Ouaiissi, I. Sielezniew, N. Pirrò, M-J. Payan, J-B. Chaix, B. Consentino, B. Sastre Paragangliome non sécrétant rétro-péritonéal À propos d'une observation: (Gastroenterol Clin Biol 2007;31:307-308)
2. V. Blin, J. Picquet, B. Enon, V. Paragangliome sécrétant de l'organe de zuckerkanndl À propos d'un cas Journal des Maladies Vasculaires (Paris) © Masson, 2002, 27, 4, 239-242
3. Trepp, Roman Kühn, Felix Stettler, Phéochromocytomes et paragangliomes fonctionnels Forum Med Suisse 2012;12(4):66-71
4. Radu Mihail Mirica, Octav Ginghina, Gabriela Zugravul, Razvan Iosifescu, Mihail Ionescu, Anca Ichiman, Adrian Rosca, Alexandra Mirica, Nicolae Iordache, Rubin Munteanu Retroperitoneal Functioning Paraganglioma - A Rare Case of Secondary Diabetes Chirurgia (2016) 111: 170-174 No. 2, March - April
5. Weifeng Xu, Hanzhong Li, Zhigang Ji, Weigang Yan, Yushi Zhang, Xuebin Zhang, Qian Li Retroperitoneal Laparoscopic Management of Paraganglioma: A Single Institute Experience Plos ONE. February 17, 2016
6. Alexandra Yannoutsos, Franck Zinzindohoue, Michel E. Safar, Jacques Blacher Paragangliome fonctionnel abdominal : à propos d'un cas de découverte fortuite Presse medicale tome 44, n89, septembre 2015.
7. Gimenez-Roqueplo AP, Favier J, Rustin P, Rieubland C, Crespin M, Nau V, Khau Van Kien P, Corvol P, Plouin PF, Jeunemaitre X, COMETE Network. Mutations in the SDHB gene are associated with extra-adrenal and/or malignant pheochromocytomas. Cancer Res. 2003; 63(17): 5615-21.
8. Mohamed Said Belhamidi, Moulay Brahim Ratbi, Mohamed Tarchouli, Tariq Adiou, Abdelmounaim Ait Ali, Aziz Zentar, Khalid Sair, An unusual localization of retroperitoneal paraganglioma: a case report Pan African Medical Journal. 2015; 22:12 doi:10.11604/pamj.2015.22.12.7437
9. Sandeep Halagatti Venkatesh, FRCR, Sarat Kumar Sanamandra, FRCR, Leng Tai Ng, Uncontrolled hypertension, palpitation and sweating in young female - A rare cause. Med J Malaysia Vol 71 No 1 February 2016
10. Gokulakrishnan Balasubramanian, Vallikantha Nellaiappan Case report Functional paraganglioma Balasubramanian G, Nellaiappan V. BMJ case rep Published online doi:10.1136/bcr-2013-203425
11. Amine Bouslama, Jaballah Sakhri Hamdi Echehoumi, Afraa Brahim, Fehmi Ferhi, Dhafer Ben Létaifa Gestion péri-opératoire d'un paragangliome rétro-péritonéal Pan African Medical Journal. 2015; 21:300 doi:10.11604/pamj.2015.21.300.6276
12. Diabaté AS, Salami FA, Séka AR, Réty F, Kanga KA, Olou L, N Zi KP Le paragangliome rétro-péritonéal: une tumeur a ne pas manipuler. J. Afr. Imag. Méd 2011; (4), 7: 391-395