

IDIOPATHIC SCLEROSING ENCAPSULATING PERITONITIS (ABDOMINAL COCOON SYNDROME)

Abdelaziz Amine, Mohammed Idrissi, Meryem H. Alami.
Taiba Multidisciplinary Clinic, Fez, Morocco.

Corresponding Author:

A.Amine, MD.

Affiliation: Gastroenterology (Private sector), Taiba Clinic, Fez, Morocco.

E-mail: polycliniquetaiba@gmail.com

Copyright © 2014- 2023 A. Amine et al. This is an open access article published under **Creative Commons Attribution -Non Commercial- No Derives 4.0 International Public License (CC BY-NC-ND)**. This license allows others to download the articles and share them with others as long as they credit you, but they can't change them in any way or use them commercially.

Available online in March 2023, Published in June 2023.

doi: 10.46327/msrjg.1.000000000000245

; doi url: <https://doi.org/10.46327/msrjg.1.000000000000245>

COMMENT:

Primary sclerosing encapsulating peritonitis, also known as abdominal cocoon syndrome is an unusual cause of bowel obstruction. If sclerosing encapsulating peritonitis may be secondary to peritoneal dialysis, tuberculosis, intraperitoneal chemotherapy or drug consumption, the idiopathic forms are exceptional. The physiopathology is an encasement of intestines by a fibrocollagenous membrane. This is a case of 53 year-old women with primary sclerosing encapsulating peritonitis admitted for bowel occlusion. Abdominal CT scan was performed (**Figures A & B**) and diagnosis was confirmed per-operatively (**Figures C & D**) [\[Video\]](#). The patient was discharged in day3. Etiological investigations were negative concluding to an idiopathic form of sclerosing encapsulating peritonitis.

Keywords: Cocoon, Idiopathic, occlusion, sclerosing peritonitis, surgery.

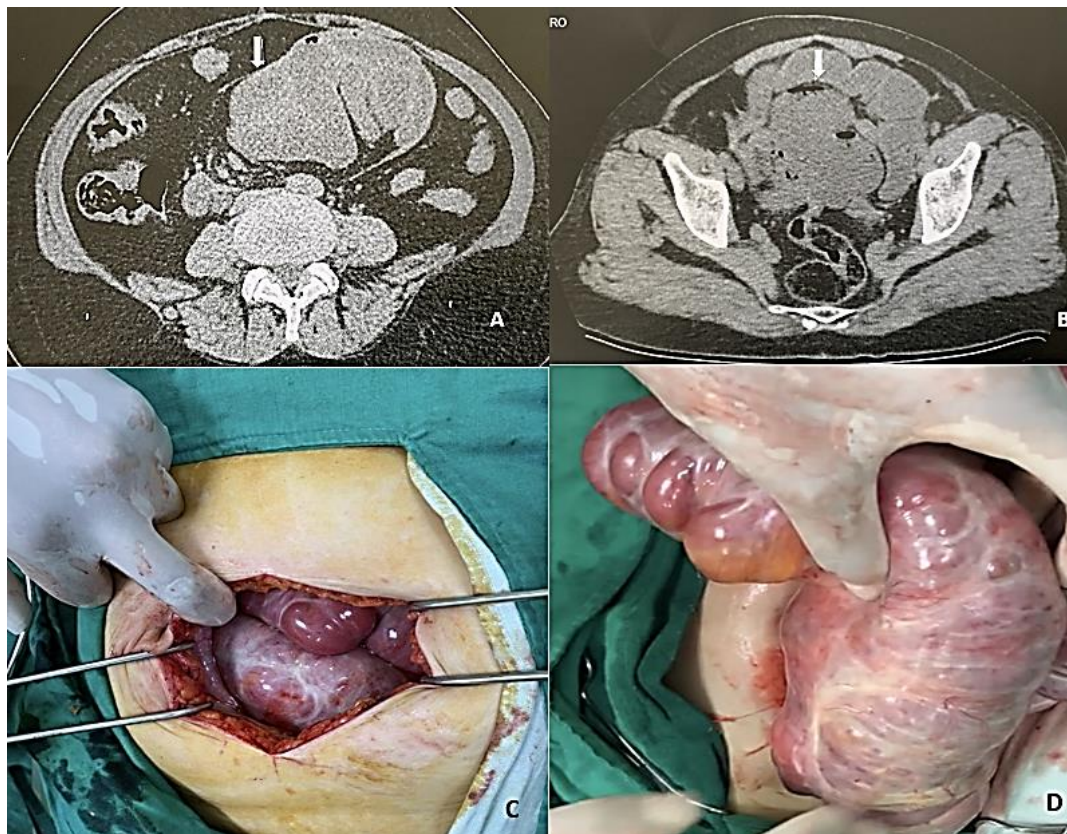


Figure A & B: CT scan images showing the fibrocollagenous membrane encapsulating intestines;
Figures C & D: Per-operative view showing intestines inside a fibrous membrane (Sclerosing encapsulating peritonitis)